

Coronectomy of the Lower Third Molar Is Safe Within the First 3 Years

Yiu Yan Leung, BDS, MDS, and
Lim Kwong Cheung, BDS, PhD†*

Purpose: There is no long-term evaluation on the safety of coronectomy of the lower third molar. The aim of this study was to investigate the 3-year morbidity of coronectomy of the lower third molars and to monitor the behavior and migration pattern of the retained roots after coronectomy.

Materials and Methods: This was a prospective cohort study. Patients with lower third molars with specific radiographic sign(s) showing proximity of the roots to the inferior alveolar nerve who underwent coronectomy in a previous randomized clinical trial were reviewed postoperatively in the first week and the third, sixth, 12th, 24th, and 36th months. The morbidities of infection, pain, root eruption, reoperation to remove the root, and the development of any pathology were recorded. The pattern of any root migration was analyzed.

Results: Ninety-eight patients (35 men and 63 women; mean age, 25.7 yrs; standard deviation, 7.9 yrs) with 135 coronectomies completed the 36-month review. None presented with infection or pain from the postoperative third month onward. Root eruption causing sensitivity occurred in 3% (4/135) of the sample and the erupted roots were removed. None of the reoperated cases presented with a postoperative inferior alveolar nerve deficit. No pathology developed in any of the retained roots after coronectomy. Root migration was noted in most cases in the first 12 months, and all roots stopped migrating from the 24th month onward. The mean root migration at 36 months was 2.8 mm (standard deviation, 1.4 mm).

Conclusions: This study confirms that retained roots after coronectomy in the lower third molars produce no complications in terms of infection, pain, or the development of pathologies within the first 3 years. Root eruption can occur in a very small percentage of patients and may require reoperation to remove the root.

© 2012 American Association of Oral and Maxillofacial Surgeons
J Oral Maxillofac Surg 70:1515-1522, 2012

Injury to the inferior alveolar nerve (IAN) is a significant complication in lower third molar surgery. It results in an IAN deficit presenting as hypoesthesia, hyperesthesia, or, worst of all, dysesthesia of the lower lip and mental region on the affected side. A proportion of these cases do not fully recover and these patients are permanently affected.¹ The surgical repair of the IAN is technically challenging, and the outcome of the repair is variable.²

Coronectomy was developed as a relatively new preventive method to decrease the prevalence of IAN injury compared with the conventional total removal of the lower third molar. The crown of the impacted lower third molar is often the cause of the food impaction, dental caries, or pericoronitis that troubles the patients. By removing the crown and leaving the root(s) behind, the problems are solved and the risk of an IAN deficit is decreased. Institutes from different parts of the world have reported success in drastically decreasing, if not eliminating, the risk of a postoperative IAN deficit by coronectomy.³⁻¹⁰ A randomized controlled clinical trial published in 2009 by the authors' center has proved that coronectomy can significantly decrease the risk of an IAN deficit in high-risk cases and is safe in terms of pain, infection rate, and dry socket, at least for the short term.⁷ Another randomized clinical trial and 2 prospective case-control trials also have shown the IAN-protective role of the technique.^{6,9,10} Another common finding has been that the retained roots tend to migrate to some extent. However, the migration of the roots and the extent

Received from the Discipline of Oral and Maxillofacial Surgery, Faculty of Dentistry, University of Hong Kong, Hong Kong.

*Clinical Assistant Professor.

†Chair Professor.

Address correspondence and reprint requests to Dr Cheung: Oral and Maxillofacial Surgery, Prince Philip Dental Hospital, 34 Hospital Road, Hong Kong; e-mail: lkcheung@hkucc.hku.hk

© 2012 American Association of Oral and Maxillofacial Surgeons

0278-2391/12/7007-0\$36.00/0

doi:10.1016/j.joms.2011.12.029

they would be expected to migrate have not been well reported.

In the era of evidence-based medicine/surgery, coronectomy has gained an increasing reputation of its effectiveness in decreasing the IAN deficit for lower third molar surgery in close proximity to the IAN. However, continuing debate on the long-term fate of the retained roots exists, and many clinicians are understandably reluctant to offer the technique as a treatment option to their patients without sufficient scientific evidence on the long-term safety of the technique.

This study was designed to answer the clinical question of whether coronectomy of the lower third molar is safe in the long term. The hypothesis of this study was that coronectomy of the lower third molar would produce minimal morbidity in the first postoperative 3 years. The aims of this study were to investigate the 3-year morbidity of coronectomy of the lower third molars and to monitor the behavior and migration pattern of the retained roots after coronectomy.

Materials and Methods

The preoperative and postoperative assessments and the surgical technique of coronectomy were adopted from the study protocol of a randomized controlled clinical trial comparing coronectomy with the conventional total removal of the lower third molars published by the authors' center in 2009.⁷ Ethical approval was granted by the local institutional review board (HKU/HA HKW IRB UW 10-001).

STUDY DESIGN/SAMPLE

To address the research purpose, the investigators designed and implemented a prospective cohort study. The study population was comprised of the patients recruited for the coronectomy group in the previous study.⁷ Patients with 1 or 2 lower third molars who underwent coronectomy were included. The procedures were performed from June 2006 through June 2008. The included patients had third molars showing at least 1 of the following radiographic signs:

1. darkening of the root
2. abrupt narrowing of the root
3. interruption and loss of the white line representing the inferior alveolar canal
4. displacement of the inferior alveolar canal by the roots
5. abrupt narrowing of 1 or 2 of the white lines representing the inferior alveolar canal

The patients were excluded if the roots were loosened or dislodged during the coronectomy procedure and were removed together, ie, an unsuccessful coronectomy.

DATA COLLECTION

Preoperatively, the patients' demographic characteristics (age and gender), tooth status (eruption status, pattern and depth of impaction, root shape, and radiographic signs), and baseline neurosensory test results were recorded.

Postoperatively, patients were reviewed at 1 week and months 3, 6, 12, 24, and 36. The following characteristics were recorded in each review appointment:

1. The presence of a lingual nerve or IAN deficit was recorded with a standardized neurosensory test, including subjective and objective assessments. A neurosensory deficit was considered present when there were subjective sensory changes and objective measurement changes, which included a light touch test and a 2-point discrimination and pain threshold test, compared with the preoperative neurosensory baseline.
2. Pain was recorded with a visual analog scale from 0 (no pain) to 10 (most severe pain).
3. The presence of infection was diagnosed from the presence of pus and pain, with or without fever.
4. The presence of a dry socket was diagnosed from the loss of a blood clot or a wound breakdown with severe pain in the early postoperative period.
5. Root eruption in the oral cavity.
6. Time and reason for the reoperation and the incidence of an IAN deficit after the reoperation.
7. Development of any pathology.

Standardized orthopantomograms (Gendex Orthoralex 9200, Kavo, Italy) were recorded at the review appointments. Root migration measurements were performed by 2 separate examiners and measured as the radiographic distance from the point of interception of the upper white line of the inferior alveolar canal and the long axis of the root to the apex of the root along the long axis (Fig 1). A magnification of $\times 1.2$ of the radiographs was adjusted for in the final measurement.

SURGICAL PROCEDURE

The surgical procedures were performed under local anesthesia, intravenous sedation with local anesthesia, or general anesthesia by the postgraduate students.

After the injection of sufficient local anesthetic (lignocaine 2% with 1:80,000 adrenaline), a 3-sided standard mucoperiosteal flap was created and raised. A lingual flap was not raised; instead, the lingual aspect was protected with a periosteal elevator. Buc-

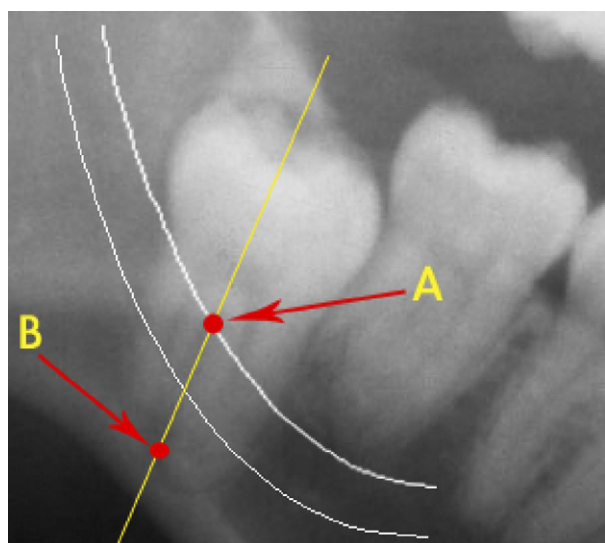


FIGURE 1. Radiographic measurement of the root position in relation to the inferior alveolar canal: the distance between point A (interception of the upper white line of the inferior dental canal and the long axis of root) and point B (the apex of the root along the long axis).

Leung and Cheung. Coronectomy of Lower Third Molar. J Oral Maxillofac Surg 2012.

cal and distal bone was then guttered with a round bur until the buccal cemento enamel junction was accessible. Decrowning of the lower third molar was performed along the cemento enamel junction with a fissure bur and, when needed, the crown was sectioned into pieces to minimize the stress to the root portion. The cut surface was trimmed to 3 to 4 mm below the bony margin. The pulp was left untouched and the root was checked for any mobility. The roots were removed if they were mobile, and the coronectomy procedure was considered unsuccessful and excluded from the study. After the wound was thoroughly debrided and irrigated with saline, it was closed primarily with resorbable polyglactin sutures. Routine analgesics with paracetamol and codeine phosphate were prescribed. No antibiotics were given.

OUTCOME MEASUREMENT

The primary outcomes of the study were the incidences of long-term morbidities, including infection, root eruption, reoperation, and pain, after coronectomy of the lower third molars. The secondary outcomes were the root migration rate and any incidence of pathology after coronectomy. The correlations between the root migration and patient/teeth status were also analyzed.

STATISTICAL ANALYSIS

Statistical analyses were performed to analyze any differences in the extent of root migration, root eruption, and reoperation in relation to age, gender, type

Table 1. PATIENT DEMOGRAPHIC AND TOOTH CHARACTERISTICS OF 98 PATIENTS WITH 135 CORONECTOMIES

Patient Demographics	
Gender	
Male	35.7% (35/98)
Female	64.3% (63/98)
Age (yrs), mean (SD)	
	27.6 (7.9)
Tooth characteristics	
Status of eruption	
Partially erupted	57% (77/135)
Unerupted	43% (58/135)
Pattern of impaction	
Vertical	17.8% (24/135)
Horizontal	43% (58/135)
Mesioangular	33.3% (45/135)
Distoangular	6.7% (9/135)
Depth of impaction (mm)	
0-4	23.7% (32/135)
5-9	52.6% (71/135)
10-14	17% (23/135)
>15	0.7% (9/135)
Root form	
Conical	36.3% (49/135)
Divergent	17% (23/135)
Parallel	46.7% (63/135)
Radiographic signs	
Darkening of root	30.4% (41/135)
Abrupt narrowing of root	0.7% (1/135)
Interruption and loss of white line of inferior dental canal	97.8% (132/135)
Displacement of inferior dental canal by the root	23.7% (32/135)
Abrupt narrowing of 1 or 2 canal white lines	4.4% (6/135)

Leung and Cheung. Coronectomy of Lower Third Molar. J Oral Maxillofac Surg 2012.

and pattern of impaction, and root form of the third molars. Data were analyzed with SPSS 19.0 (SPSS Inc, Chicago, IL). A probability level of 5% was set as statistically significant.

Results

Coronectomies were successfully performed in 155 lower third molars in 108 patients. Among these, 98 patients (35 men, 63 women) with 135 coronectomies completed the 36-month follow-up. Fifteen patients with 20 coronectomies refused follow-up during this period owing to work commitments or personal reasons and were excluded from the study. The dropout rate was 12.9% (20/155). The mean age of the patients was 27.6 years (standard deviation [SD], 7.9 yrs). The teeth characteristics and the distribution of radiographic signs are presented in Table 1.

One case of an IAN deficit was present in a 29-year-old woman after coronectomy of a lower right third

molar. She presented with moderate hypoesthesia of the right lower lip at the first week of review. The lower lip sensation recovered to normal at the 12-month review. There was no incidence of lingual nerve deficit in any case. No dry socket occurred after coronectomy in any patient.

The long-term morbidities after coronectomy of lower third molars are described below.

INFECTION

Six of 135 cases (4.4%) developed a wound infection in the first postoperative week. All were treated with antibiotics and debridement, with or without pus drainage. The infection subsided uneventfully. There was no incidence of infection of the coronectomies from months 3 to 36 postoperatively.

PAIN

Pain in the first postoperative week was reported in 58 of 135 cases (43%), with a mean pain visual analog scale of 3.0 of 10. Apart from the 4 patients with exposed roots who complained of "sensitivity to cold food or water" or "discomfort" at the lower third molar area, no subjects complained of any pain at the subsequent reviews up to the 36-month follow-up appointment.

ROOT ERUPTION AND REOPERATION

Four of 135 cases (3%) presented with root eruption after coronectomy of the lower third molars. Three presented with root eruption with sensitivity to cold drinks and the other had an asymptomatic root eruption. The root eruption occurred at postoperative month 9 in 1 case, at postoperative month 18 in 1 case, and at postoperative month 24 in 2 cases. All 4 cases underwent reoperation to remove the retained root. No postoperative IAN deficit or other morbidities occurred after any reoperation.

The mean age of the 4 patients with root eruption leading to reoperation was significantly older than the mean age of the patients without root eruption (39.5 yrs [SD, 5.8 yrs] vs 27.2 yrs [SD, 7.7 yrs], $P = .002$). Distoangular impaction also carried a higher risk of root eruption compared with the other patterns of impaction ($P = .004$). Gender of the patient, depth of impaction, and the root form of the third molars were not found to be related to the risk of root eruption after coronectomy of the lower third molars (Table 2).

ROOT MIGRATION

Most roots migrated in the first 12 months after coronectomy, and 75.2% of roots stopped migrating from 12 to 24 months postoperatively. For the roots that did not erupt in the oral cavity, none of the retained roots showed further migration from 24 to 36 months. No reactivation of root migration occurred in any patient. The root migrations of the

lower third molars with different patterns of impaction are illustrated in Figure 2.

The mean total root migration at postoperative months 6, 12, 24, and 36 were 1.9 mm (SD, 1.1 mm), 2.6 mm (SD, 1.3 mm), 2.9 mm (SD, 1.6 mm), and 2.8 mm (SD, 1.4 mm), respectively (Fig 3). The mean change of the root position during the intervals of 0 to 6 months, 6 to 12 months, 12 to 24 months, and 24 to 36 months were 1.9 mm (SD, 1.1 mm), 0.7 mm (SD, 0.6 mm), 0.3 mm (0.6 mm), and 0 mm, respectively.

Because there was no further root migration after 24 months in the present subjects, statistical analyses were performed to investigate the correlation of the total movement of the root at 24 months to the age and gender of the patients, the pattern and depth of impaction, and the root form of the lower third molars. The root migration in female patients (3.2 mm; SD, 1.7 mm) was significantly greater compared with their male counterparts (2.4 mm; SD, 1.2 mm; $P = .014$). No other factors were found to correlate to total root migration at 24 months or after (Table 3).

DEVELOPMENT OF PATHOLOGY

No pathology developed in the retained roots during the entire review process. No apical pathologies related to the retained roots were noted.

Discussion

The randomized clinical trial conducted by the authors' center and several other studies comparing coronectomy

Table 2. COMPARISON OF FACTORS AFFECTING ROOT ERUPTION AFTER CORONECTOMY

	Root Erupted	Root Not Erupted	<i>P</i>
Age (yrs), mean (SD)	39.5 (5.8)	27.2 (7.7)	.002
Gender			.139
Female	4.8% (4/83)	95.2% (79/83)	
Male	0	100% (52/52)	
Type of impaction			.004
Vertical	4.2% (1/24)	95.8% (23/24)	
Horizontal	1.8% (1/57)	98.2% (56/57)	
Mesioangular	0	100% (45/45)	
Distoangular	22.2% (2/9)	77.8% (7/9)	
Depth of impaction (mm)			.535
0-4	6.3% (2/32)	93.7% (30/32)	
5-9	2.8% (2/71)	97.2% (69/71)	
10-14	0	100% (23/23)	
>15	0	100% (9/9)	
Root form			.857
Conical	2% (1/49)	98% (48/49)	
Divergent	4.3% (1/23)	95.7% (22/23)	
Parallel	1.6% (1/63)	98.4% (62/63)	

Leung and Cheung. Coronectomy of Lower Third Molar. J Oral Maxillofac Surg 2012.

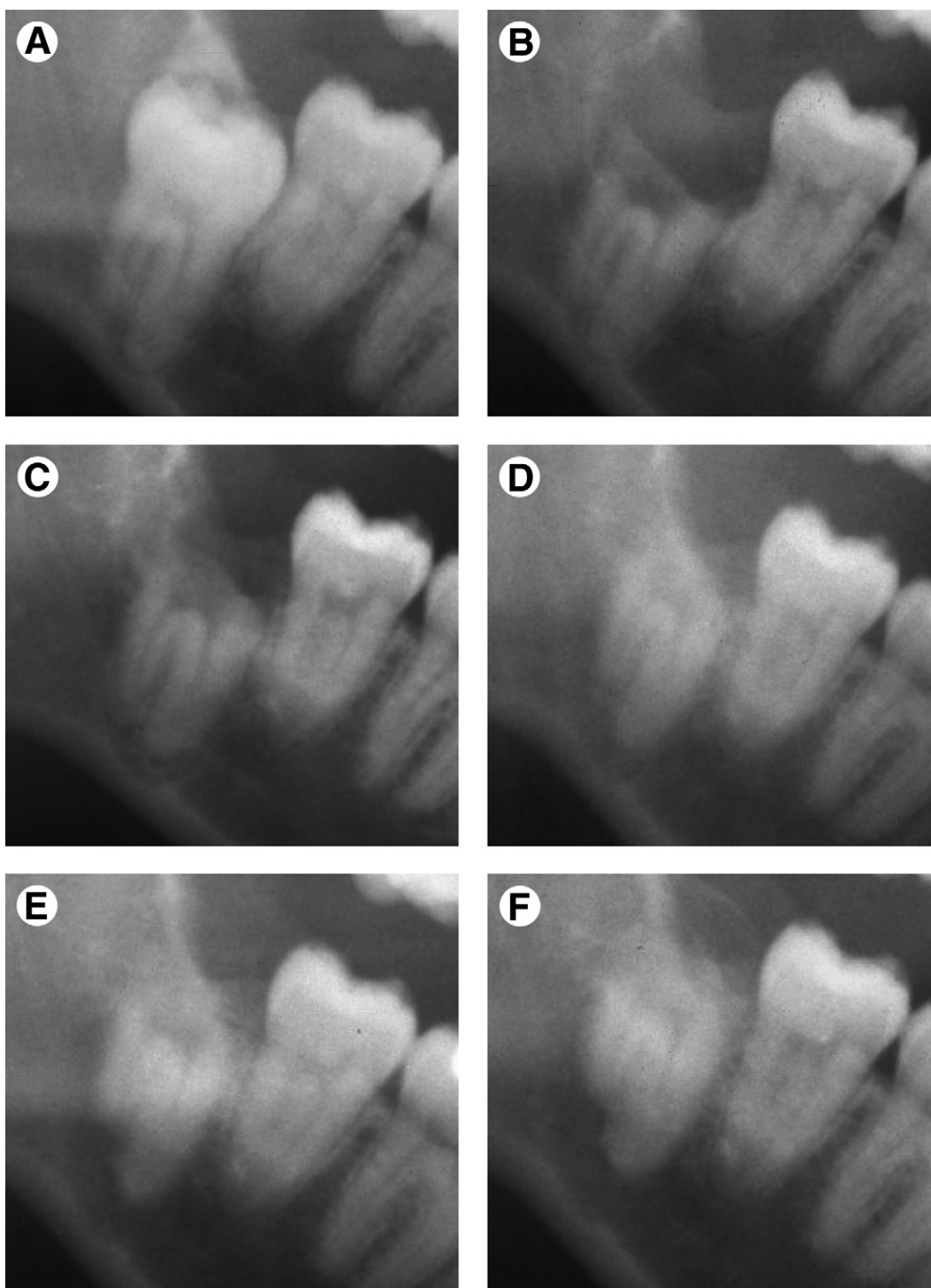


FIGURE 2. Pattern of root migration after coronectomy for impacted third molars over 3 years: A, preoperative; B, 1 week postoperatively; C, 6 months postoperatively; D, 12 months postoperatively; E, 24 months postoperatively; F, 36 months postoperatively.

Leung and Cheung. Coronectomy of Lower Third Molar. J Oral Maxillofac Surg 2012.

with the total removal of the lower third molars have shown, with a sufficient sample size, that an IAN deficit after coronectomy can be significantly decreased in high-risk cases.^{6,7,9,10} The present study supports that this technique is safe in the long-term up to at least 3 years.

Many clinicians worry about infection of the retained roots after coronectomy in the long-term. Some have suspected that the pulpal tissue would undergo necrosis after coronectomy, leading to apical periodontitis or osteomyelitis.^{11,12} Although animal

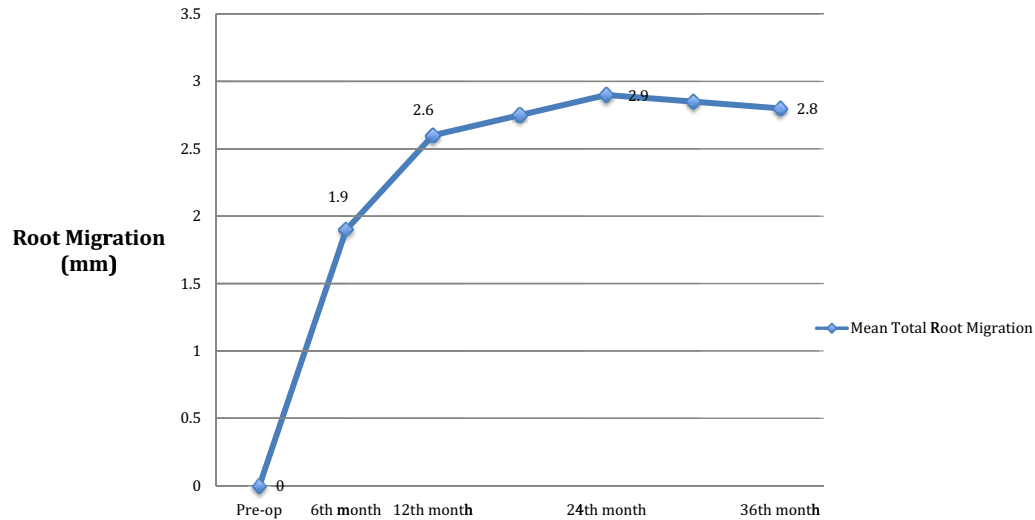


FIGURE 3. Mean total root migration after coronectomy.

Leung and Cheung. Coronectomy of Lower Third Molar. J Oral Maxillofac Surg 2012.

studies have proved that retained roots after decoronation procedures can retain pulpal viability,¹³ it is not yet enough to convince clinicians that the retained root will not cause any problems to their patients until long-term clinical results become available. Several studies have reported that early infection (1 week to 1 mo postoperatively) can occur, but the incidences were not significantly higher than the total removal counterpart.^{3,5,7} In the randomized clinical trial published by the authors' center, a slightly lower

infection rate was found compared with total removal, but no statistical difference between the 2 groups was noted.⁷ These infections were easily managed with routine antibiotics and debridement with or without the drainage of any pus collection. In their sample, the authors noted that cases of acute infection did not become chronic in nature or affect the embedded roots. None of the roots showed any clinical or radiographic signs of apical periodontitis or late infection from month 3 to month 36 of follow-up, which is consistent with most other studies with a shorter follow-up period. It has been suggested that infected roots might cause paresthesia of the IAN. The present findings showed no development of a late neurosensory disturbance of the IAN, which further fosters the belief of a viable retained root after coronectomy. Endodontic treatment of the root canal after coronectomy was not needed in any case. Interestingly, Sencimen et al¹⁴ reported a higher failure rate when they performed root canal treatment after coronectomy. In their study, 7 of 8 roots treated with endodontia were subsequently removed because of infection. From the present study, there is no medical evidence to support the notion that retained roots require any elective endodontics.

Surgical pain within the first postoperative week generally is expected by the patients. The 2 available randomized clinical trials have shown that pain in coronectomy cases is actually less compared with the total excision of third molars.^{6,7} Pain was not reported in any of the follow-ups from 3 months onward. One interesting finding was that 4 patients who developed root eruption after coronectomy complained of "sensitivity" to cold food or water, which

Table 3. COMPARISON OF FACTORS AFFECTING TOTAL ROOT MIGRATION (AT 24 MONTHS OR AFTER)

	Root Migration (mm), Mean (SD)	<i>P</i>
Age, correlation	-0.95	.286
Gender		.014
Female	3.2 (1.7)	
Male	2.4 (1.2)	
Type of impaction		.522
Vertical	3.1 (1.6)	
Horizontal	2.8 (1.3)	
Mesioangular	3.1 (1.4)	
Distoangular	2.3 (1.0)	
Depth of impaction		.858
0-4	2.9 (1.6)	
5-9	3.0 (1.6)	
10-14	2.7 (1.0)	
>15	2.9 (1.8)	
Root form		.156
Conical	3.0 (1.6)	
Divergent	3.1 (1.8)	
Parallel	2.6 (1.4)	

Leung and Cheung. Coronectomy of Lower Third Molar. J Oral Maxillofac Surg 2012.

was a sign of a living root retaining a temperature sensibility.

Root migration is a common finding in almost all studies on coronectomy of the lower third molars.³⁻⁶ However, the extent and behavior of root migration have not been well reported in the literature. Pogrel et al⁴ reported that only 30% of subjects had signs of migration, and Renton et al⁶ reported that around one third of the roots had migrated at the time of their patients' last review. Dolanmaz et al⁸ reported that root migration reached 4 mm at 24 months postoperatively. In the present study, almost all roots migrated in the first year, and only one fourth kept migrating from months 12 through 24 postoperatively. Once root migration had stopped, there was no reactivation of root migration observed in the present sample. From this study, 24 months postoperatively seems to be the watershed of root migration because 1) if a root migrates to an extent that leads to root eruption into the oral cavity, it will occur within the first 24 months; and 2) none of the retained roots migrated farther after 24 months postoperatively. These key findings provide a better understanding of the root behavior after coronectomy. This study is also the first attempt to investigate the factors affecting the extent of root migration. Although most factors seem to be unrelated, it is surprising to note that roots migrated to a greater extent in female than in male patients. The reason for this difference remains unclear at this stage.

Root eruption is thought to be related to the extent of root migration. Although some studies have not reported any incidence of root eruption,^{6,8} an equal number of studies have reported a 5.5% to 6% reoperation rate owing to subsequent root eruption into the oral cavity.^{4,5} In the present larger sample, there was a 3% incidence of root eruption occurring within the first 24 months. A further analysis showed that older patients carried a higher risk of root eruption, and distoangular impaction contributed a higher risk of eruption into the oral cavity compared with other patterns of impaction. It is of clinical importance to note that none of the reoperations to remove an erupted root caused a neurosensory disturbance of the IAN. This supports the logical thinking that, as the root moves closer to the surface, it will be farther away from the nerve and carry a much smaller risk of nerve injury compared with removing the roots from their original situation.

For many years, there have been attempts to decrease the risk of IAN injury in lower third molar surgery. The various risk factors of IAN injury have been investigated extensively.¹⁵⁻¹⁹ Advances in imaging, such as cone beam computed tomography, have gained popularity in recent years and provided enormous help to clinicians in understanding the 3-dimen-

sional relation of the proximity of the root to the nerve. However, before coronectomy was known, surgeons and patients had no choice but to take the risk of a permanent IAN injury because symptomatic lower third molars have a close relation to the IAN. Recently, several techniques have been proposed to remove wisdom teeth with a high risk of injury to the IAN with the aim of decreasing the chance of an IAN injury.²⁰⁻²³ Although these techniques can decrease the risk of IAN injury, their drawbacks involve 2 or more surgical/operative procedures. In the authors' opinion, some of these techniques would even increase the morbidities and discomfort of the patients.²⁴ Coronectomy has proved to be an effective 1-stage procedure in decreasing the risk of IAN injury and has been found to be safe for up to 3 years. Coronectomy is the best treatment alternative for third molars with roots in close proximity to the IAN. However, the authors do not advise performing coronectomy on third molars with dental caries likely to involve the dental pulp or already presenting with apical pathologies. A longer review of the fate of the roots after coronectomy of the lower third molars is of academic interest, as is the periodontal health of the distal second lower molar adjacent to the retained roots.

This study shows that coronectomy of the lower third molar is safe in the long term up to 3 years postoperatively. The roots retained after coronectomy of the lower third molars showed no complications in infection, pain, or the development of pathologies at 36 months postoperatively. The retained roots migrated forward/upward in most cases in the first year, gradually slowed down, and stopped migrating from 24 months onward. Three percent of the roots erupted in the alveolus and caused sensitivity symptoms, which occurred within the first 24 months postoperatively. Reoperation to remove the erupted root did not cause any IAN deficit in this study.

Acknowledgments

The authors thank Mr Andy Hon Kwan Chan and Miss Karen Kar Yan Lai for their contributions in data collection and root migration measurement. They also express their gratitude to the postgraduates of the discipline who performed the surgical procedures.

References

1. Cheung LK, Leung YY, Chow LK, et al: Incidence of neurosensory deficits and recovery after lower third molar surgery: A prospective clinical study of 4338 cases. *Int J Oral Maxillofac Surg* 108:821, 2009
2. Farole A, Jamal BT: A bioabsorbable collagen nerve cuff (NeuraGen) for repair of lingual and inferior alveolar nerve injuries: A case series. *J Oral Maxillofac Surg* 66:2058, 2008
3. Freedman GL: Intentional partial odontectomy: Review of cases. *J Oral Maxillofac Surg* 55:524, 1997
4. Pogrel MA, Lee JS, Muff DF: Coronectomy: A technique to protect the inferior alveolar nerve. *J Oral Maxillofac Surg* 62:1447, 2004

5. O'Riordan BC: Coronectomy (intentional partial odontectomy of lower third molars). *Oral Surg Oral Med Oral Pathol Oral Radiol Endod* 98:274, 2004
6. Renton T, Hankins M, Sproate C, et al: A randomised controlled clinical trial to compare the incidence of injury to the inferior alveolar nerve as a result of coronectomy and removal of mandibular third molars. *Br J Oral Maxillofac Surg* 43:7, 2005
7. Leung YY, Cheung LK: Safety of coronectomy versus excision of wisdom teeth: A randomized controlled trial. *Oral Surg Oral Med Oral Pathol Oral Radiol Endod* 108:821, 2009
8. Dolanmaz D, Yildirim G, Isik K, et al: A preferable technique for protecting the inferior alveolar nerve: Coronectomy. *J Oral Maxillofac Surg* 67:1234, 2009
9. Hatano Y, Kurita K, Kuroiwa Y, et al: Clinical evaluations of coronectomy (intentional partial odontectomy) for mandibular third molars using dental computed tomography: A case-control study. *J Oral Maxillofac Surg* 67:1806, 2009
10. Cilasun U, Yildirim T, Guzeldemir E, et al: Coronectomy in patients with high risk of inferior alveolar nerve injury diagnosed by computed tomography. *J Oral Maxillofac Surg* 69:1557, 2011
11. Assael LA: Coronectomy: A time to ponder or a time to act? *J Oral Maxillofac Surg* 62:1445, 2004
12. Garcia-Garcia A: Coronectomy: A questionable procedure. *J Oral Maxillofac Surg* 63:723, 2005
13. Plata RL, Kelln EE, Linda L: Intentional retention of vital submerged roots in dogs. *Oral Surg Oral Med Oral Pathol* 42:100, 1976
14. Sencimen M, Ortakoglu K, Aydin C, et al: Is endodontic treatment necessary during coronectomy procedure? *J Oral Maxillofac Surg* 68:2385, 2010
15. Bruce RA, Frederickson GC, Small GS: Age of patients and morbidity associated with mandibular third molar surgery. *J Am Dent Assoc* 101:240, 1980
16. Kipp DP, Goldstein BH, Weiss WW Jr: Dysesthesia after mandibular third molar surgery: A retrospective study and analysis of 1,377 surgical procedures. *J Am Dent Assoc* 100:185, 1980
17. Carmichael FA, McGowan DA: Incidence of nerve damage following third molar removal: A West of Scotland Oral Surgery Research Group study. *Br J Oral Maxillofac Surg* 30:78, 1992
18. Gülicher D, Gerlach KL: Sensory impairment of the lingual and inferior alveolar nerves following removal of impacted mandibular third molars. *Int J Oral Maxillofac Surg* 30:306, 2001
19. Leung YY, Cheung LK: Risk factors of neurosensory deficits in lower third molar surgery: An literature review of prospective studies. *Int J Oral Maxillofac Surg* 40:1, 2011
20. Ramaraj PN: Orthodontic extraction: The riskless extraction of the impacted lower third molars close to the mandibular canal. *J Oral Maxillofac Surg* 66:1317, 2008
21. Landi L, Manicone PF, Piccinelli S, et al: A novel surgical approach to impacted mandibular third molars to reduce the risk of paresthesia: A case series. *J Oral Maxillofac Surg* 68:969, 2010
22. Landi L, Manicone PF, Piccinelli S, et al: Staged removal of horizontally impacted third molars to reduce risk of inferior alveolar nerve injury. *J Oral Maxillofac Surg* 68:442, 2010
23. Tolstunov L, Javid B, Keyes L, et al: Pericoronary ostectomy: An alternative surgical technique for management of mandibular third molars in close proximity to the inferior alveolar nerve. *J Oral Maxillofac Surg* 69:1858, 2011
24. Leung YY, Cheung LK: Does staged removal of lower third molars pose unnecessary re-operations to patients? *J Oral Maxillofac Surg* 68:2924, 2010